

# Galactorrhoea and hyperprolactinaemia in a non-pregnant female with burns

Marli van Heerden, Dineo Mabuza

*Department of Chemical Pathology, University of the Witwatersrand and National Health Laboratory Service,  
Johannesburg, South Africa*

---

## ARTICLE INFO

### **Corresponding author:**

Dr. Dineo Mabuza,  
Department of Chemical Pathology  
University of Witwatersrand  
Wits Medical School  
7 York Road, Parktown, 2193  
Johannesburg  
South Africa  
Phone: +27(11) 489-8762  
Fax: +27(11) 489-8451  
E-mail: [dineo.mabuza@nhls.ac.za](mailto:dineo.mabuza@nhls.ac.za)

### **Key words:**

chest burns, galactorrhoea,  
prolactin, hyperprolactinaemia

---

## ABSTRACT

Galactorrhoea is the presence of breast milk secretion in non-pregnant or non-breastfeeding females. In females with galactorrhoea and amenorrhoea, hyperprolactinaemia is the most likely cause. Chest wall pathology is a known cause of hyperprolactinaemia, however there are few documented reports on galactorrhoea following burn injury to the chest wall. We report a case of an adult female patient who sustained hot water burns to her torso. Following the second skin graft failure, galactorrhoea was noted and investigated. Hyperprolactinaemia was found with normal renal and thyroid function. There were no abnormalities detected on the hormones in the hypothalamic pituitary axis and MRI. Hyperprolactinaemia was attributed to chest wall injuries causing pathological stimulation of the neural suckling reflex. The patient was treated with dopamine agonists for one month and the galactorrhoea disappeared. Treatment was discontinued on discharge and the prolactin levels remained normal upon follow-up visit to the clinic.

## INTRODUCTION

Galactorrhoea indicates the presence of milk secretion from the breast in the absence of pregnancy or more than 6 months postpartum in a woman not breastfeeding (1). Milk production is under the influence of the hormone prolactin, secreted by the anterior hypothalamus; its secretion is mainly controlled by the inhibitory effect of dopamine (1,2). Factors that inhibit dopamine secretion and clearance of prolactin have an effect on prolactin levels. These include diet, stress, exercise, renal & liver disease, hypothyroidism, high oestrogen states, medication and chest wall pathology (2). High prolactin levels result in decreased luteinizing hormone (LH) and follicle stimulating hormone (FSH) by inhibition of release of gonadotropin releasing hormone and may result in amenorrhoea (3).

Although chest wall pathology is a known cause of galactorrhoea with hyperprolactinaemia, there are few reported cases of patients with chest wall burns. We report a case of galactorrhoea with hyperprolactinaemia in an adult female with chest wall burns.

## CLINICAL-DIAGNOSTIC CASE

A 28-year old female, presented to the emergency unit, in May 2018 with hot water burns to her chest following a domestic dispute. She was 31 weeks pregnant and subsequently progressed to premature labour for which a caesarean section was performed. The baby demised one month later. There was no significant past medical or surgical history.

A skin graft to the chest area was performed (Figure 1) and she was discharged to follow up at the outpatient clinic for wound care. She was readmitted in September for graft failure due to sepsis and her treatment included antibiotics and wound dressings. The second skin graft was performed in October and subsequently

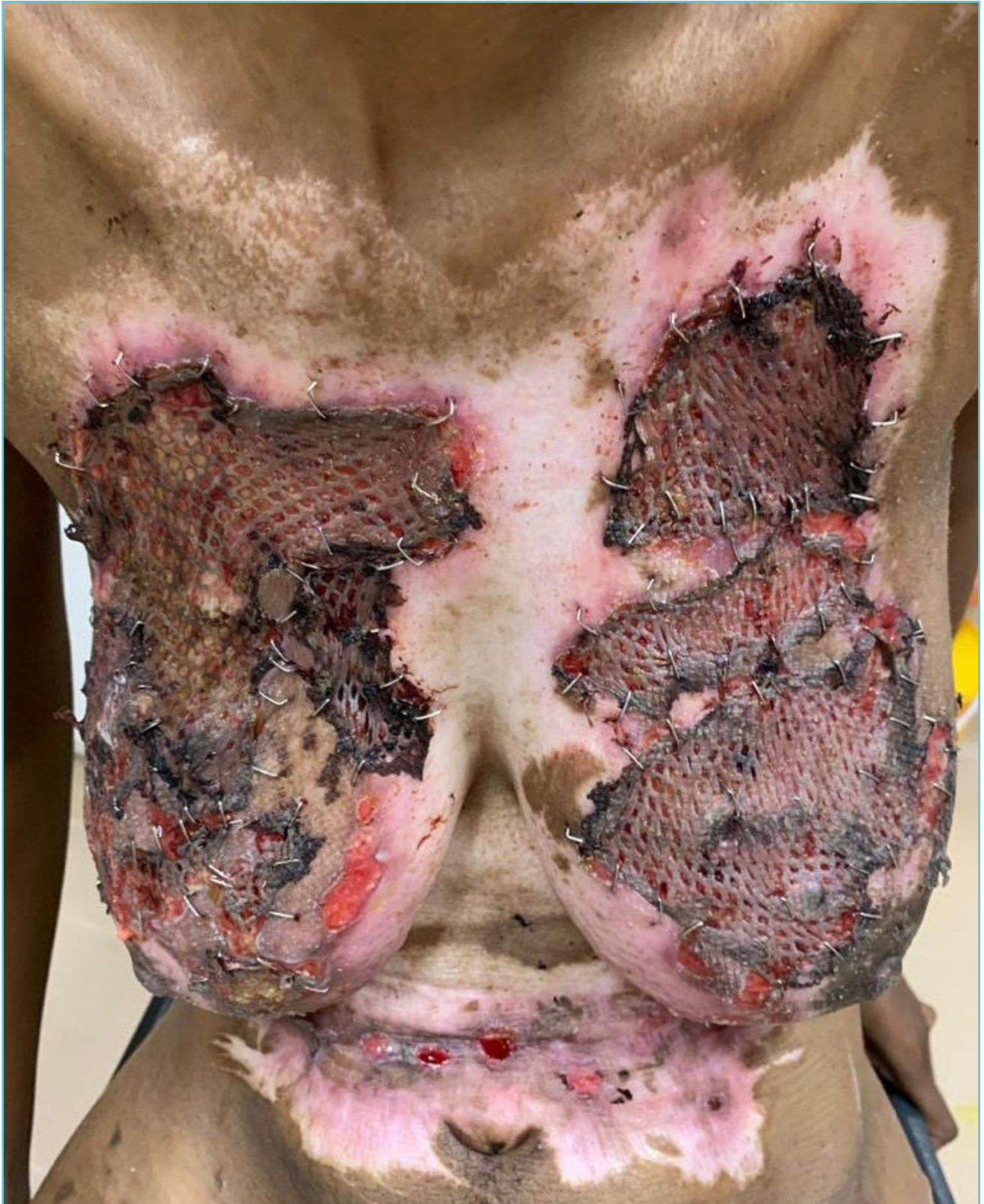became septic. She presented with pus on both breasts and Methicillin Resistant Staphylococcus was cultured and found to be sensitive to Vancomycin. She was treated with Vancomycin and discharged home for wound care at the outpatient clinic. Despite the antibiotic therapy the graft failed.

In February 2019, she was readmitted for wound sepsis. Galactorrhoea was noted and endocrinologists were consulted. She reported occasional headaches and absent menses but no visual disturbances. Her last menstrual cycle was prior to the pregnancy and she was not on any contraceptives. She denied illicit drug use and was not on any dopamine antagonists. On examination there was no evidence of hirsutism, acne and hyperpigmentation.

Pregnancy was excluded by means of a urine human chorionic gonadotropin (hCG) point of care test in the ward. Serum prolactin was measured and found to be markedly elevated (353.7 µg/L, reference interval (RI), 4.8-23.3 µg/L). Macroprolactin was excluded in the laboratory by polyethylene glycol (PEG) precipitation. This procedure is performed with PEG solution (25% w/v), prepared by dissolving PEG 6000 in phosphate buffered saline (PBS) stock solution and PBS buffer. An equal volume of the patient sample and PEG solution was mixed and allowed to incubate at room temperature for ten minutes. The PEG was precipitated by centrifugation, after which the supernatant was analysed. The post-PEG monomeric prolactin was 249.5 µg/L (RI, 3.5-18 µg/L) which confirmed true hyperprolactinaemia. The renal function and other hormones in the hypothalamic pituitary axis were assessed (Table 1).

Levels of creatinine, estimated glomerular filtration rate (eGFR), thyroid stimulating hormone (TSH), free T4 (fT4), human growth hormone (hGH), insulin-like growth factor 1 (IGF-1) and

**Figure 1** The patient with severe burn wounds post skin graft





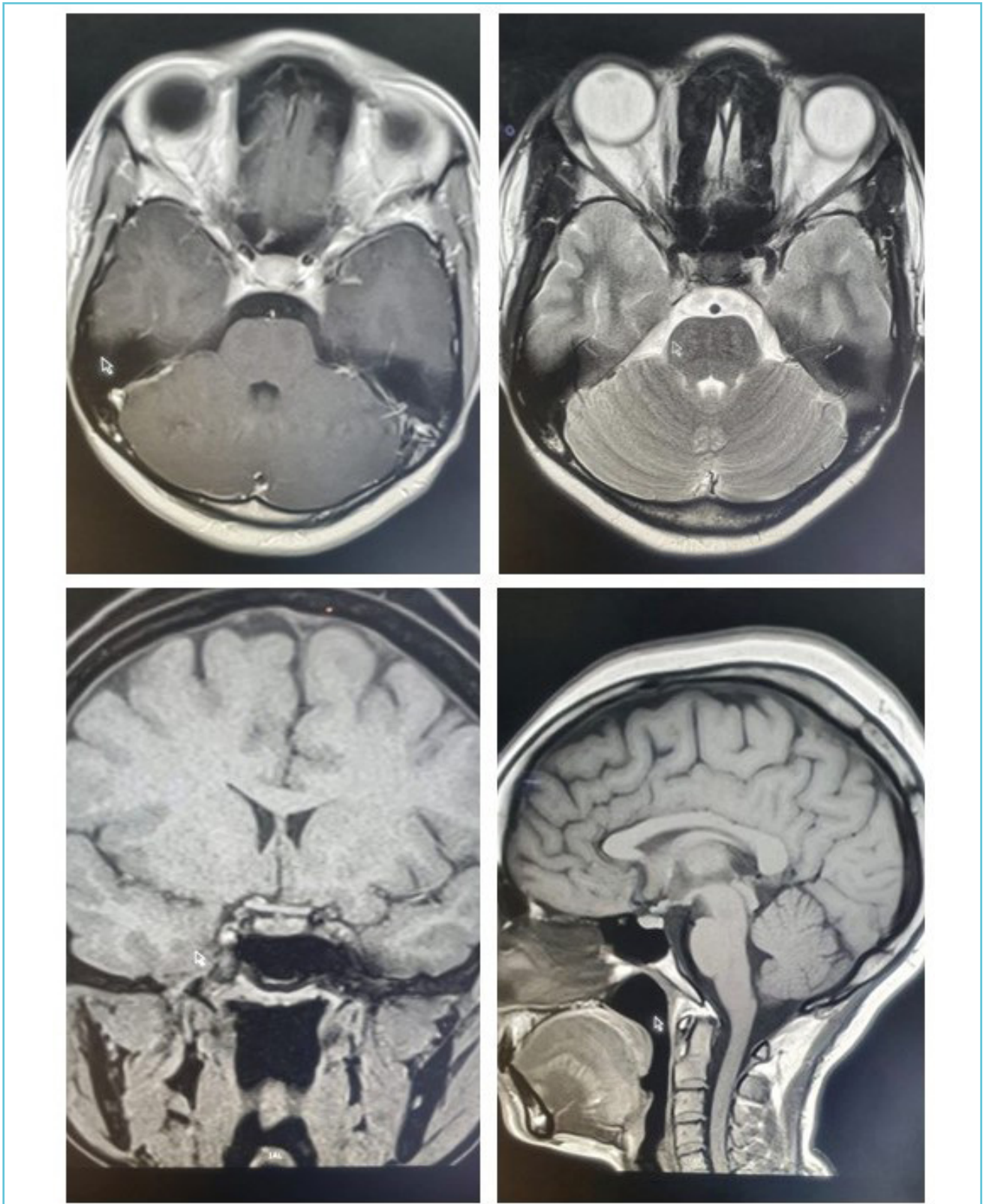
**Table 1** Selected biochemical results

| Test            | Reference interval   | Test results (19/02/2019) |
|-----------------|--|---------------------------|
| Creatinine      | 49-90 µmol/L   | 59                        |
| eGFR (MDRD)     | > 60 ml/min/1.73m <sup>2</sup>   | > 60                      |
| TSH             | 0.27-4.20 mIU/L  | 2.1                       |
| ft4             | 12.0-22.0 pmol/L   | 12.6                      |
| FSH             | Follicular phase: 3.5 -12.5 IU/L<br>Ovulation phase: 4.7 - 21.5 IU/L<br>Luteal phase: 1.7 - 7.7 IU/L<br>Postmenopausal: 25.8 - 134.8 IU/L      | 6.3                       |
| LH              | Follicular phase: 2.4 - 12.6 IU/L<br>Ovulation phase: 14.0 - 95.6 IU/L<br>Luteal phase: 1.0 - 11.4 IU/L<br>Postmenopausal: 7.7 - 58.5 IU/L     | 16.4                      |
| Estradiol       | Follicular phase: 45 – 854 pmol/L<br>Ovulation phase: 151 – 1461 pmol/L<br>Luteal phase: 82 – 1251 pmol/L<br>Postmenopausal: (<18 – 505 pmol/L | 107                       |
| hGH             | 0.13 - 9.88 µg/L   | 0.5                       |
| IGF-I           | 88-537 µg/L  | 140                       |
| ACTH            | 1.6-13.9 pmol/L  | 2.6                       |
| Random Cortisol | Morning (06:00-10:00): 133 – 537 nmol/L<br>Afternoon (16:00-20:00): 68 – 327 nmol/L  | 205                       |

adrenocorticotrophic hormone (ACTH) were all within the reference intervals. A Magnetic resonance imaging (MRI) scan (Figure 2) revealed a normal pituitary gland and stalk with no evidence of infiltratory disease or a tumour.

The patient was treated with a dopamine agonist for one month and the galactorrhoea disappeared. Her prolactin levels were within the reference interval on discharge and at 1 week follow up (Table 2).

Figure 2 The patient's MRI of the brain that shows no pituitary pathology



**Table 2** Prolactin results

| Reference interval | 15/02/2019 | 19/02/2019* | 21/02/2019 | 04/03/2019# | 25/03/2019* |
|--------------------|------------|-------------|------------|-------------|-------------|
| 4.8 – 23.3 µg/L    | 353.7      | 20.3        | 21.6       | 1.2         | 0.9         |

\*post initiation of bromocriptine; #2 weeks on therapy; \*1 week post discharge.

## DISCUSSION

There are three forms of prolactin in the circulation: monomeric (23kDa), dimeric and the biologically inactive polymeric prolactin (>100kDa), also known as macroprolactin (3,4). Most immunoassays detect biologically active and inactive forms and results may not reflect the true biological activity (4). Thus, macroprolactin must be excluded to avoid unnecessary investigations or interventions (4,5). In our patient the monomeric prolactin remained elevated post PEG precipitation. Due to the fact that a small amount of monomeric prolactin can be precipitated, post-PEG reference ranges were used (6). Other methods that can remove macroprolactin include gel filtration chromatography, ultrafiltration and antibody binding techniques (4). PEG precipitation is routinely used in most laboratories as it is the least expensive and shows the best correlation with gel-filtration chromatography which is regarded as the gold standard (4,6). Dynamic function testing is not recommended (5).

Once it is confirmed that there is true hyperprolactinaemia, pregnancy should be excluded first (7). The high oestrogen concentration found in pregnancy stimulates prolactin synthesis and results in hyperprolactinaemia (1,2). In addition, the patient was also not on any oestrogen containing contraceptives. The use of dopamine antagonists such as antipsychotics, antihypertensives, antidepressants and metoclopramide was excluded. Illicit drugs and opioids, which are known for inhibition of dopamine release,

were also excluded (2,5,7). Decreased renal clearance of prolactin in chronic kidney disease causes hyperprolactinaemia (1,2,5). Primary hypothyroidism can result in diffuse pituitary enlargement, stimulation of prolactin release by thyrotropin releasing hormone and decreased prolactin clearance from the systemic circulation (2). However, our patient had normal renal and thyroid function.

Once all the above had been excluded, hypothalamic-pituitary disease may be considered (7). A prolactin secreting tumour is the most common pathologic cause of hyperprolactinaemia (1). Prolactin levels >250 µg/L, as seen in this patient, are suggestive of a prolactinoma (5). However, there were no hypothalamic-pituitary lesions noted on MRI.

With the exclusion of all the common causes, the most obvious cause of the galactorrhoea and hyperprolactinemia was the chest burns. The mechanism of hyperprolactinaemia in chest wall injuries is the pathological stimulation of the neural suckling reflex (1,8). The burn wounds are sensitive to touch and the stimuli pass along the intercostal nerves to the posterior column of the spinal cord and finally to the hypothalamus where dopamine release is inhibited (1,9). The patient did not breastfeed post-delivery and she received Bromocriptine to stop lactation. According to the patient, the galactorrhoea started in October but was not reported to the clinicians. The presence of galactorrhoea may explain the septic wounds and graft failure. A moist environment, due to

galactorrhoea, may inhibit incorporation of the graft into the wound bed and provide a favourable environment for bacterial growth. In addition, the presence of galactorrhoea may have caused wet dressings, which resulted in their early and inappropriate removal by the patient; thus, providing an opportunity for exposure of the wound to bacteria.

A study by Goyal et al in India found the incidence of amenorrhoea and/or galactorrhoea in female patients with chest burns to be 15.15%. According to the authors one of the reasons why this condition might be under reported is due to patients not volunteering the information unless prompted (9). Karimi and colleagues (10) reported a case of galactorrhoea that started three months after discharge and responded well to therapy. Their patient had developed hypertrophic scars and keloids despite preventative treatment and skin grafting. The authors claim that this time period correlates with collagen deposition and scar contraction and that the hyperprolactinemia observed during this anabolic period may be related to the development of refractory hypertrophic scars (10).

Galactorrhoea associated with amenorrhoea and hyperprolactinaemia requires treatment (7). The aim of therapy is to restore normal gonadal function and fertility as well as prevent osteoporosis (2). Prolactin levels were successfully reduced on medical therapy in our patient and she was discharged without any medication. It is imperative that she is monitored for recurrence of galactorrhoea and possibly measurement of prolactin at follow up visits.

This case demonstrates the importance of recognizing chest wall pathology as a cause of hyperprolactinemia. Clinicians should specifically ask all women with chest wall burns about galactorrhoea. The presence of galactorrhoea and amenorrhea following chest wall burns should

prompt clinicians to investigate for hyperprolactinemia which can be effectively treated with dopamine agonists.

### TAKE HOME MESSAGES/ LEARNING POINTS

1. In females with galactorrhoea and amenorrhoea, hyperprolactinaemia is the most likely cause.
2. Most immunoassays detect the various forms of prolactin, therefore, macroprolactin must be excluded before further investigations.
3. Chest wall pathology is not a common cause of hyperprolactinaemia, however it should be considered in burn patients presenting with galactorrhoea.
4. Chest wall pathology results in pathological stimulation of the neural suckling reflex which inhibits the release of dopamine by the hypothalamus.
5. Medical therapy, with dopamine agonists, is an effective management strategy for galactorrhoea with hyperprolactinaemia



### *Author disclosures & contributions*

1. Written informed consent was obtained from the patient for publication of this case report and any accompanying images.
2. Ethics was obtained from the Medical Human Research Ethics Committee. Protocol number M190296.
3. The authors declare that they have no competing interests.
4. M van Heerden and D Mabuza interviewed the patient, analysed and interpreted the patient data, and were the major contributors in writing the manuscript. All authors read and approved the final manuscript.

### **Acknowledgements**

We would like to thank Dr. Sarah Melissa Katzew for the clinical information and images of the burns and Dr. Nadege Ntumba for the MRI images.



### **REFERENCES**

1. Leung AKC, Pacaud D. Diagnosis and management of galactorrhea. *Am Fam Physician*. 2004;70(3):543-50.
2. Serri O, Chik CL, Ur E, Ezzat S. Diagnosis and management of hyperprolactinemia. *CMAJ*. 2003;169(6):575-81.
3. Bernard V, Young J, Chanson P, Binart N. New insights in prolactin: pathological implications. *Nat Rev Endocrinol*. 2015; 11:265-75.
4. Kavanagh L, McKenna TJ, Fahie-Wilson MN, Gibney J, Smith TP. Specificity and Clinical Utility of Methods for the Detection of Macroprolactin. *Clin Chem*. 2006;52(7): 1366-72.
5. Melmed S, Casanueva FF, Hoffman AR, Kleinberg DL, Montori VM, Schlechte JA, et al. Diagnosis and Treatment of Hyperprolactinemia: An Endocrine Society Clinical Practice Guideline. *J Clin Endocrinol Metab*. 2011;96(2): 273-88.
6. Beltran L, Fahie-Wilson MN, McKenna TJ, Kavanagh L, Smith TP. Serum total prolactin and monomeric prolactin reference intervals determined by precipitation with polyethylene glycol: Evaluation and validation on common immunoassay platforms. *Clin Chem*. 2008;54(10):1673-81.
7. Huang W, Molitch ME. Evaluation and management of galactorrhea. *Am Fam Physician*. 2012;85(11):1073-80.
8. Jones RE, Gulati M. Hypothalamic and Pituitary Function. In: Bishop ML, Fody EP, Schoeff LE, editors. *Clinical Chemistry: Principles, Techniques, and Correlations*. 7th ed. Philadelphia, PA: Lippincott Williams & Wilkins; 2013. p. 438-52.
9. Goyal N, Gore MA, Shankar R. Galactorrhea and amenorrhea in burn patients. *Burns*. 2008;34(6):825-8.
10. Karimi H, Nourizad S, Momeni M, Rahbar H, Momeni M, Farhadi K. Burns, hypertrophic scar and galactorrhea. *J Inj Violence Res*. 2013;5(2):117-9.